A CASE OF DIFFUSE HYPERTROPHY OF THE BREASTS.

BY

JAMES BELL, M.D.,
Professor of Clinical Surgery, McGill University; Surgeon to the Royal Victoria Hospital, Montreal.

Reprinted from the Montreal Medical Journal, October, 1899.

A CASE OF DIFFUSE HYPERTROPHY OF THE BREASTS.*

BY

JAMES BELL, M.D.,

Professor of Clinical Surgery, McGill University; Surgeon to the Royal Victoria Hospital, Montreal.

This patient, a healthy, well-developed and well-nourished French-Canadian girl, seventeen years of age, from a country district, was admitted to the Royal Victoria Hospital, on the 3rd of August, 1899, with enormous hypertrophy of both breasts, as shown in the accompanying photographs. She was of a healthy family, with no known pathological heredity. She began to menstruate at the age of fifteen, but that function had always been somewhat irregular both in the duration of the period and the length of the interval, though otherwise normal. Her colour was good, and nothing abnormal was found about any of the organs with the exception of a slight trace of albumin in the urine.

The breasts were very large, painless, and moderately pendulous. On palpation, the sensation communicated to the hand was that of a partially filled sac of fluid containing freely moveable, hard, fleshy masses. Just below the nipple of the left breast, was a patch of ulceration as large as a half-dollar coin, the result of pressure gangrene. Large veins ramified over the surfaces of both breasts.

She had first noticed in November, 1898, that the breasts were large, but it was only in March, 1899, that the enlargement became very marked. From that time they had increased in size very rapidly, but without pain. The ulceration had begun two weeks before admission.

The left breast was removed on August 7th, and weighed 6½ pounds. The right was removed on August 26th, and weighed 5 pounds and 13 ounces. The skin over the surface of each breast was greatly thinned and the subcutaneous cellular tissue much condensed, so that it was dissected off with difficulty. The underlying connective tissue was also much condensed. On section, there appeared to be a general hypertrophy of both glandular and fibrous tissues, and all the tissues were very firm. Professor Adami kindly examined sections from the left breast, and the following are extracts from his report :—

"It is not pure hypertrophy of the gland tissue, though that must be present, but is essentially, I take it, an orderly hyperplasia of the fibrous tissue,—granuloma of the same. The abundant connective tissue between the alveoli is too perfectly formed to allow the condition to be spoken of

* Read by title at the Meeting of the Canadian Medical Association, Toronto September 1st, 1899.

as fibromatous. If I may use the term, there is here a 'cheloid' overgrowth of the connective tissue."

This condition, though somewhat rare, is well known, and is described in most surgical works and monographs upon the diseases of the female breast. I quote the following sentence from Dennis (System of Surgery, Vol. IV., page 895) :—"The disease has been known according to Selbet since the time of Galen, and has been described by Velpeau, Billroth, and others." It generally occurs in young girls, and is symmetrical, and though no definite cause can be assigned for it, it is thought to be in some way associated with the function of the genital organs, and is therefore often attributed to masturbation, etc. As for treatment, nothing can be done to arrest the hypertrophy once it has begun and removal of the breasts soon becomes necessary on account of their great size.

id.' over-
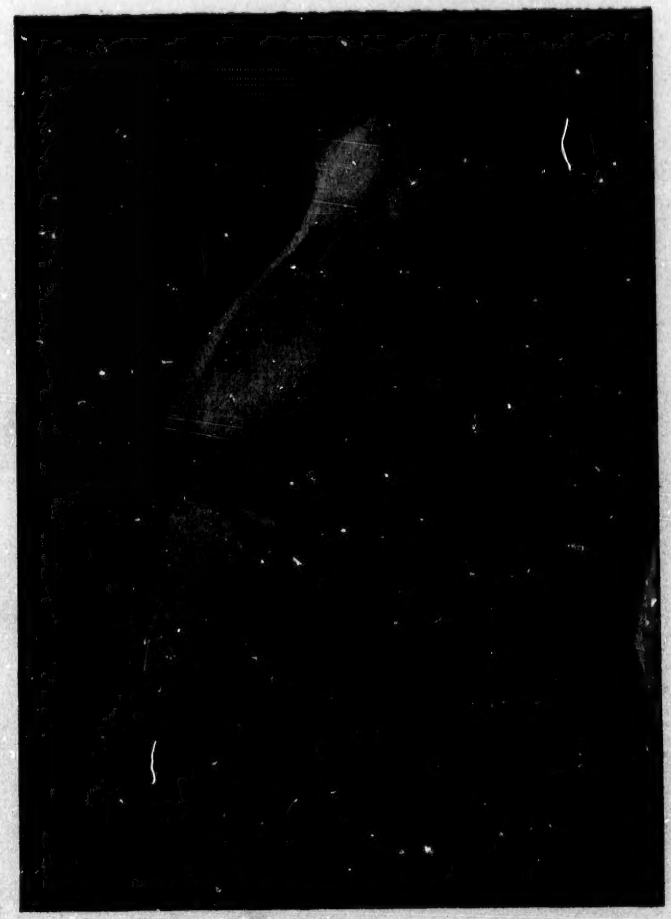
described
ne female
of Sur-
ording to
Velpeau,
s symme-
thought
gans, and
reatment,
egun and
heir great